SWEDISH

Swedish's TAVR** team has given Tom Goldader a **new lease on life.
See page 6.

Doc Talk

Published for health-care professionals.

IN THIS ISSUE

1 New Epilepsy Treatment
Treating Aortic Valve Stenosis
2 Case Study: Brain Stimulation to Control Seizures
3 Measured Approach to Proton Therapy
4 Lytle Center Open House
Options for Gallbladder Patients
5 A Cautious Approach to Knee Surgery
Case Study: Segond Fracture and ACL Tear
Case Study: Meniscus Tear and Meniscal Cyst
6 Case Study: Transcatheter Aortic Valve Replacement
7 Swedish Quick Reference
8 Continuing Medical Education
New Members of Swedish Medical Staff

FDA Panel Unanimously Supports Benefits of New Epilepsy Treatment

Ryder Gwinn, M.D., Director of Epilepsy and Functional Neurosurgery, Swedish Epilepsy Center

The Swedish Neuroscience Institute was one of 32 centers that participated in a double-blind, randomized clinical trial to determine whether an implanted NeuroPace RNS® System device could reduce seizure frequency in adult patients with epilepsy. The device is the first significant new treatment for epilepsy since 1997.

At the conclusion of the study in 2010, NeuroPace sought approval for the device from the U.S. Food and Drug Administration (FDA). In February of this year, the FDA's Neurological Devices Panel voted unanimously, with two abstentions, that the clinical benefits of the RNS System outweigh the risks of its use. The final decision by the FDA is expected this summer.

Treatment options for epilepsy include drugs, surgical resection and nerve stimulation. Whereas surgery remains the gold standard of treatment options, the RNS System provides new hope for patients who are not candidates for surgery, such as those with bilateral temporal lobe epilepsy, and for those who have failed medication.

The NeuroPace device consists of a neurostimulator, which is implanted in the skull and

(continued on page 2)

Experience Counts When Treating Patients with Aortic Valve Stenosis

The Swedish Heart & Vascular Institute (SHVI) is one of the few places in the Pacific Northwest able to offer treatment options for patients with severe aortic valve stenosis – even those who are not candidates for open-heart surgery due to age, frailty or other co-morbidities. SHVI's interventional cardiologists and cardiovascular surgeons have significant experience and expertise with both surgical and transcatheter aortic valve replacement (AVR).

The primary cause of aortic stenosis is calcification and narrowing of the valve, thereby limiting cardiac output. Aortic stenosis affects an estimated 5 percent of people age 75 and older. Valve replacement is the only cure for aortic stenosis; without it, 50 percent of these patients will survive less than two years after symptom onset.

Identifying the best option

"We have an AVR evaluation process based on a deep-seated collaboration among medical, surgical, nursing and ancillary specialties," says **Glenn R. Barnhart, M.D.**, chief of Cardiac Surgery and surgical director of the Structural Heart Program. "It is this comprehensive evaluation that ensures each patient is offered the best possible treatment option."

Evaluations for surgical aortic valve replacement (SAVR) and transcatheter aortic valve replacement (TAVR) are similar. Studies include echocardiogram, cardiac catheterization, CT scan, pulmonary function testing and carotid artery ultrasound. Objective measures are used to evaluate frailty, a formal diagnosis encompassing strength, mobility, nutrition and tissue integrity. The assessment also includes the Society for Thoracic Surgeons (STS) risk calculator, a tool to help quantify mortality and morbidity risk due to major adverse events.

The majority of patients with severe aortic stenosis are deemed candidates for SAVR, which is typically performed as an open-heart

(continued on page 6)

New Epilepsy Treatment

(continued from page 1)

connected to electrodes that are implanted directly onto the brain surface precisely where the seizures originate. The battery-operated neurostimulator continuously monitors brain activity. When the detector senses a seizure, the electrodes emit a pulse of energy designed to short circuit the seizure before it spreads throughout the brain.

Currently, vagus nerve stimulation (VNS) therapy is the only FDA-approved form of neuromodulation to treat epilepsy. Frequently, however, significant seizure reduction is not achieved with VNS.

Despite a more challenging population of patients implanted with

(continued on next page)

An Illustrated Case Report: Brain stimulation helps control seizures when nothing else can

Ryder Gwinn, M.D., Director of Epilepsy and Functional Neurosurgery, Swedish Epilepsy Center

Childhood: As a baby, Brian was late walking and in meeting other developmental milestones. He had mild right-side weakness, which led to a diagnosis of cerebral palsy. Brian had his first seizure at the age of eight. An MRI showed an area of abnormal brain development in the left frontal lobe known as schizencephaly. For the next three decades his physicians tried every known antiepileptic drug. At times he was on five medications simultaneously. Nothing worked.

Age 41: Brian underwent an extensive evaluation at the Swedish Epilepsy Center at the Swedish Neuroscience Institute (SNI) to determine if he was a candidate for surgery. Testing included video EEG monitoring, neuropsychological testing, a Wada test, and an MRI of the brain tailored to identify abnormalities peculiar to patients with epilepsy. He also underwent an ictal SPECT and PET scan to identify the brain areas causing seizure activity.

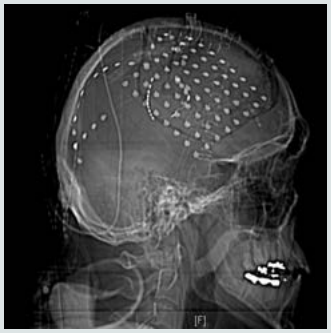

Lateral view of Brian's skull during intracranial monitoring for seizure localization.

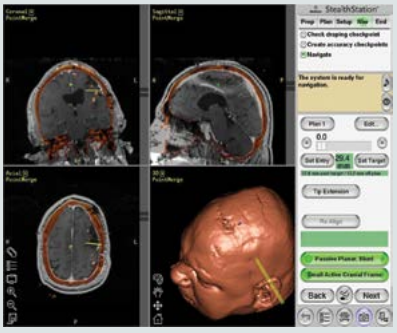

Intraoperative neuronavigation points to location of Brian's seizure focus in real time for precise electrode placement.

The SNI epilepsy team developed a consensus recommendation that Brian would benefit from surgery. More precise localization of the seizure focus was performed using special platinum electrodes placed directly on the surface of the brain, which revealed seizures coming from an area adjacent to the developmental abnormality. Brian underwent surgery to remove the seizure focus. He initially did well following surgery; however, the seizures returned, but with different clinical features. Further trials of medications were unsuccessful. The seizures became more frequent, often occurring hundreds of times each day.

Age 44: In 2006 Brian underwent a SISCOM study and additional video EEG monitoring. Electrodes localized seizures to two areas in the left frontal lobe. The functions of the frontal lobe were mapped and it was determined that one area could be safely removed. The second area controlled right-arm movements, which made removal inadvisable. Following removal of the first area, Brian was seizure free for only four months.

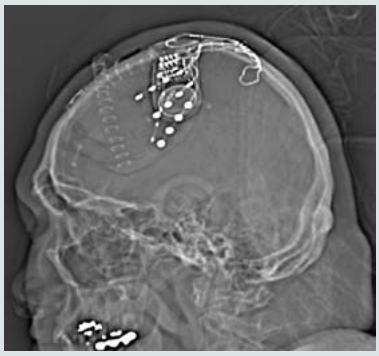

Lateral view of Brian's skull with implanted RNS device including pulse generator and electrodes.

Age 45: Brian developed episodes of right-hand twitching, progressing to daily motor seizures affecting the entire right side of his body. Knowing that further surgery was not advisable, Brian agreed to a NeuroPace RNS® System implant.

Today: Brian is now doing very well. His seizures have nearly stopped since the device was implanted. Every three to four

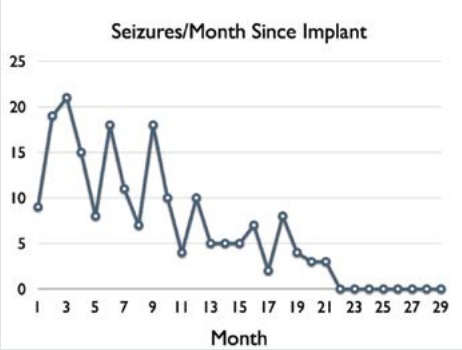

months he occasionally will have arm tremors, which last for a few seconds and then go away. He has gone white-water rafting, and is able to take the bus and travel independently. Brian remains on medication, but now has a very positive outlook on his future.

A Measured and Disciplined Approach to Proton Therapy

Vivek Mehta, M.D., Medical Director, Centers for Advanced Radiation Therapy, the Swedish Cancer Institute

The emergence and increased availability of proton therapy for cancer patients has created considerable commentary and some controversy among leaders in radiation therapy. Some individuals claim the biological and physical characteristics of protons are so favorable that one day it might replace traditional radiotherapy altogether.

For more than 76 years, the Swedish Cancer Institute (SCI) has been a leader and pioneer in developing, testing and adopting new radiotherapy technologies. In regards to proton therapy, we have chosen to take a measured and disciplined approach to how we incorporate this technology into the care of our patients.

Unlike traditional X-rays or photons, protons are charged particles. When they are accelerated, they can deposit most of their energy in a specified depth range – called the Bragg Peak. There is speculation that this characteristic will enable more energy to be deposited at the cancer and less energy deposited in surrounding normal tissues; thereby, hopefully reducing toxicity and side effects.

While I am attracted to these theoretical benefits, it is in the best interest of our patients for us to rigorously assess whether:

- The plans created on a proton machine are better dosimetrically
- The patient will realize a clinical benefit
- We are cognizant of the costs relative to the benefits for the patient and for society

Evaluating dosimetry

One of the limitations of delivering proton therapy is that the technology does not account for geometric or positional variations of the target or normal tissues, which can occur due to movement or setup uncertainty. Therefore, to ensure the target is not missed due to these variables, the area to be treated is often larger. In contrast, photon or X-ray radiotherapy utilizes more sophisticated treatment planning, more angles and more intensity modulation to achieve higher doses in smaller, more specified volumes. Additionally, X-ray or photon technology incorporates "image guidance," which improves delivery precision and accuracy, and provides important information about changes in the shape and size of the target.

The jury is still out on improved outcomes

In 2011 the Advisory Committee of the American Registry of Radiation Technology issued a report indicating that for a few tumor sites (pediatrics, ocular and chordomas of the skull base), proton therapy is potentially advantageous. For the majority of sites, however, the report indicated there was no conclusive data, or outcomes were very similar to other radiation therapies.

Nationwide, proton therapy has been widely adopted for prostate cancer, with prostate cancer accounting for approximately 75 percent of all proton therapy treatments. And yet, according to the Advisory Committee's report, the results are no better than with other radiation therapy platforms. Some people have suggested that consideration in treating patients with prostate cancer is primarily economic. The investment in a proton facility is substantial. In many instances, to build a center might cost more than $100 million. The only way to cover those costs is to treat a commonly diagnosed cancer, such as prostate cancer.

A different approach at the SCI

At the Centers for Advanced Radiation Therapy at the SCI, we believe in advancing technology in a measured and disciplined

(continued on next page)

When to Refer to Swedish

The Swedish Cancer Institute offers the most extensive selection of radiation therapy on the West Coast. With their years of experience and access to the full range of therapy options, the SCI's nationally recognized experts are able to guide their patients to the optimal course of treatment. Available technologies include:

- 4-D electromagnetic localization (Calypso®)
- 4-D PET/CT targeting
- 4-D treatment planning, including proton treatment planning
- Active Breathing Coordinator™
- Brachytherapy
- Image-Guided Radiation Therapy (IGRT)
- Intensity-Modulated Radiation Therapy (IMRT)
- Laser-guided surface mapping
- Liver-directed therapies (TheraSphere®)
- Localized internal radiation therapy
- Radioimmunotherapy
- Respiratory gated radiotherapy
- Stereotactic radiosurgery (CyberKnife® and Gamma Knife®)
- TomoTherapy®
- Volmetric-Modulated Arc Therapy (VMAT)

Swedish/Ballard
Radiation Treatment Center
206-386-6707

Swedish/Cherry Hill
Radiosurgery Center
206-320-7130

Swedish/Edmonds
Radiation Oncology
425-640-4300

Swedish/First Hill
Radiation Oncology
206-386-2323

Swedish/Issaquah
Radiation Oncology
425-313-4200

The SCI at Highline Medical Center
Radiation Oncology
206-386-2626

New Epilepsy Treatment

(continued from page 2)

the RNS System, long-term results showed a significant reduction in seizure frequency post implant of 44 percent at one year and 53 percent at two years. Some patients have had no seizures or only a rare seizure since implantation.

If the FDA approves this therapy, the Swedish Neuroscience Institute will be the only center in the Pacific Northwest to offer treatment with the RNS System. For more information, call **206-320-3852.**

Please Join Us at the Lytle Center VIP Open House

The providers and staff of The Lytle Center for Pregnancy & Newborns cordially invite you to see where life's greatest journey begins. We hope you can join us in celebrating the center's opening at our special Providers and Staff Open House on Friday, Aug. 2, from 3 to 8 p.m., at Swedish/First Hill in Seattle.

The Lytle Center is a dedicated resource for moms, newborns and families during the first few weeks following delivery. It will be open seven days a week, with weekday evening hours beginning July 31. Services at the center include:

- Clinical appointments for new moms and well-baby checkups shortly after delivery
- Clinical and social work support for postpartum mood disorder
- Breastfeeding support from certified lactation nurse consultants
- Breast pump rentals and other lactation supplies
- Childbirth, parenting and family education classes
- Fitness classes for pregnant and postpartum moms
- Support groups for expectant parents, siblings and grandparents
- Baby changing and weighing station
- Dedicated retail with necessities for childbirth, parenting and wellness
- Happy Birth Day get-acquainted tours and pre-birth tours at Swedish/First Hill

For more information about The Lytle Center for Pregnancy & Newborns, go to www.swedish.org/thelytlecenter or call **206-386-BABY (206-386-2229)**.

The Lytle Center Provider and Staff Open House

When: Friday, Aug. 2, from 3 to 8 p.m.

Where: 747 Broadway, Seattle, Wash. 98122. The entrance is located on Cherry Street, between Broadway and Minor Avenue.

Parking: Broadway parking garage, located at 747 Broadway

Please let us know you will be attending by calling **206-386-6797** or going online to www.swedish.org/TLCOpenHouse.

Surgical Options for Gallbladder Patients

Over the years technology has advanced the art of surgery, allowing surgeons to consider more than one technique. Thus is the case with cholecystectomy – and with the expanding capability of surgeons at Swedish.

Until the early 1990s open surgery, requiring one four- to eight-inch abdominal incision, was the standard treatment for removing the gallbladder. As with any major surgery, the hospital stay and recovery can be lengthy, and limits to the patient's activities extend for four to six weeks.

The laparoscopic cholecystectomy, which was first performed in 1987, replaced open surgery as the standard approach because of its multiple benefits. A lap chole typically requires four small (1-2½ cm) incisions. Ninety-five percent of lap chole patients go home the same day and resume normal activities within a week. The resulting overall reduction in direct-care costs is dramatic.

The newest technology is robotics and the Single-Site® Cholecystectomy. Using the da Vinci® surgical system, surgeons are able to remove the gallbladder through one, small incision in the umbilicus. Procedure time, risk of infection, length of stay, and reduced pain and blood loss are comparable to the laparoscopic approach.

"The 3-D visualization, 10-X magnification, dampened movements and extra degree of articulation compared to standard laparoscopy afford greater precision, which is especially helpful in our more complex cases," says **Ryan Martinez, M.D.**, a surgeon with Swedish Surgical Specialists. "While Swedish will continue to evaluate the overall benefits of the single-site platform, the clear benefit to the patient is a nearly invisible scar."

Swedish is a regional center for performing – and teaching – robotic surgery, and has made da Vinci surgical systems available at three of its campuses (Edmonds, First Hill and Issaquah).

Surgeons with Swedish Surgical Specialists are skilled in all three approaches to cholecystectomy. For more information or to consult on a patient or seek a second opinion, please call **206-215-3500**.

Proton Therapy

(continued from page 3)

way – using an approach that promotes evidence-based decisions, places the patient at the center of deliberations and ensures treatment choices that first and foremost benefit the patient. Currently, we are testing a proton treatment-planning system to evaluate in a systematic fashion which patients might benefit from this therapy. We also are actively involved in planning for the next generation proton therapy system that promises to overcome some of the current limitations of the existing systems.

We offer an extensive menu of radiation therapies because we know there often are a number of ways to treat a particular cancer and that the treatment decision needs to be personalized for each patient. An evaluation by one of our experts, assures a balanced and thoughtful review of all options available to the patient. We invite you to call us at **206-386-2323** to consult on a particular patient, to request a second opinion or to inquire about treatment locations and options, including proton radiation therapy.

Cautious Approach to Knee Injuries

High-impact sports and activities with twisting motions are particularly hard on adult knees. The unpleasant truth is that it takes less force to tear the meniscus when we are in our 40s and 50s than when we were younger. Thirty years ago athletes and "weekend warriors" with knee injuries faced open surgery with all of the accompanying side effects – large incisions, risk of infection, pain and a lengthy recovery. Today orthopedic surgeons using non-surgical therapies and arthroscopic surgical techniques can get men and women with knee injuries back into action more quickly.

Surgeons at the Swedish Orthopedic Institute use a cautious approach with knee injuries, such as meniscus and ligament tears, cartilage defects and patella dislocations/stabilizations.

"We prefer pursuing non-surgical treatment options first," says **Camille Clinton, M.D.**, ProOrtho orthopedic surgeon at Swedish/Redmond. "Bracing, injections, rest and physical therapy often resolve minor injuries without surgery. If those fail, however, we typically turn to arthroscopic surgery."

Arthroscopic surgery provides many benefits for the patient, including:

- No hospital stay
- Small incisions
- Minimal tissue disruption
- Faster recovery
- Less pain (many patients require pain medication for less than a day)
- Less risk of infection
- Less risk of stiffness
- No crutches
- Back to work quickly

Following arthroscopic knee surgery, most patients are able to resume their normal activities within four to six weeks with physical therapy to help regain their strength.

For more information, or to consult on a specific patient or to seek a second opinion about surgical necessity, please call **425-823-4000**. For more information about all orthopedic services available at Swedish, go to www.swedish.org/orthopedics.

Case Study: Arthroscopic Knee Surgery Following Skiing Accident

Camille Clinton, M.D., ProOrtho, Swedish/Redmond

A very active 53-year-old female presented to our clinic with a knee injury she suffered while skiing. She indicated she had gone over her skis and felt a pop in her knee. The mountain rescue team brought her down the hill on a toboggan. She was using a knee immobilizer and crutches when she arrived at our office a couple of days after the incident.

Image 1. A radiograph obtained during an urgent care visit shows evidence of a Segond fracture.

The exam was notable for effusion, limited range of motion and a positive Lachman test, which is used with a suspected anterior cruciate ligament (ACL) tear. Radiographs, which were acquired during a visit to urgent care, showed a Segond fracture (an avulsion fracture of the lateral aspect of the tibial plateau), consistent with ACL tear. *(see image 1)* An MRI confirmed the ACL tear *(see image 2)*, as well as a medial meniscus tear.

Image 2. An MRI (anterior view) confirmed the ACL tear. Medial meniscus tear is not visible on this image.

The patient's goal was to continue her active lifestyle, so she opted for ACL reconstruction and partial medial meniscectomy using arthroscopic techniques.

She was back to work as a teacher within three weeks, jogging at four months and skiing again the following winter with no pain or instability.

Case Study: Arthroscopic Knee Surgery for Injury of Unknown Origin

Camille Clinton, M.D., ProOrtho, Swedish/Redmond

A 65-year-old female presented with a three-month history of knee pain and swelling. She did not recall injuring her knee, but symptoms had been persistent. She initially saw her primary-care provider, who ordered an MRI and referred her to our clinic.

Her exam was notable for medial joint line tenderness and an effusion. MRI showed a large medial meniscus tear with associated meniscal cyst, and mild-to-moderate chondromalacia in the medial and patellofemoral compartments.

Because of the continued presence of symptoms, the patient elected to undergo arthroscopic knee medial meniscectomy. Post-operatively she took one pain pill and was back to work on post-op day two. She returned to all of her normal activities by week six, without pain or limitation.

Image 1. Arrow points to medial meniscus tear and cyst.

Image 2. Arrow points to medial meniscus tear.

(continued from page 1)

procedure. Patients with an STS risk score of 8 percent or greater, however, are considered at increased risk for open-heart surgery and the conventional SAVR procedure. Up until recently, these elderly and/or fragile patients had no alternative treatment option.

Study results lead to TAVR approval

In late 2011, the U.S. Food and Drug Administration (FDA) approved the use of the Edwards SAPIEN transcatheter heart valve for the treatment of patients with severe, symptomatic native aortic valve stenosis who are at prohibitive risk for open-heart surgery.

"As investigators in the PARTNER clinical study, we gained a great deal of experience with TAVR," says **Robert M. Bersin, M.D.**, an interventional cardiologist and medical director of SHVI's Structural Heart Program. "We are pleased that our published results helped gain FDA approval and that we are now able to expand

(continued on next page)

Case Study: TAVR Gave Tom a New Lease on Life

Mark Reisman, M.D., Interventional Cardiology, Swedish Heart & Vascular Institute

Eighty-five-year-old Tom Goldader was referred to us in July 2012 for aortic valve replacement. Mr. Goldader has a medical history that includes controlled hypertension, hyperlipidemia, interstitial lung disease with a history of asbestos exposure, stage III renal disease, moderate anemia, gastroesophageal reflux disease, unspecified hepatitis diagnosed in 1954 and non-insulin diabetes mellitus. His prescription medications include: levothyroxine, glipizide, rosuvastatin, amlodipine, carvedilol, meclizine and doxazosin. He has a family history of diabetes, heart disease and stroke. He has not smoked in more than 40 years and does not drink alcohol. His chief complaint was that he feels weak and gets short of breath with minimal exertion. He also reported getting dizzy during moderate activity and that he has had an episode of syncope.

In 2005, Mr. Goldader had stents placed in his left and right internal carotid arteries. TTE acquired during the next five years showed moderate calcification in the aortic valve leaflets with moderate aortic stenosis. In August 2010, a stress echocardiogram showed moderate-to-severe reduction in exercise capacity. The stress test was stopped due to a drop in systolic blood pressure from 160 to 134, blunted heart rate response and dyspnea.

In 2008 and again in 2010, Mr. Goldader underwent right and left heart catheterization and coronary angiography. By April 2012, TTE showed severe calcific aortic stenosis.

Our thorough evaluation of Mr. Goldader for aortic valve replacement began in July and continued through September. CTA showed severe ascending aortic calcification that was nearly circumferential in some areas, which precluded the possibility of reasonable acceptable risk for cardiopulmonary bypass in the aortic cross clamping. His STS risk score for mortality was 12.0 percent. His blood workup indicated significant abnormalities and he met the frailty threshold. His functional status was declining and he could not walk 100 feet without having to stop and rest.

The TAVR team carefully reviewed the results of all diagnostic studies. Cohort B Guidelines for Surgical AVR deemed him inoperable due to porcelain aorta. After extensive discussion, the team concluded Mr. Goldader would benefit from transfemoral TAVR. We also determined that his left ileofemoral arteries were suitable for access for the 23-mm Edwards SAPIEN valve. He was scheduled for TAVR in early October.

The procedure, which was performed under general anesthesia, included left femoral cutdown, right and left heart catheterization, balloon aortic valvuloplasty and transcatheter aortic valve replacement with the 23-mm Edwards SAPIEN valve.

At his one-month follow-up appointment, Mr. Goldader was doing extremely well with no chest pain. In fact, his wife complained that she was having trouble "slowing him down" and they were planning a trip to Palm Desert.

In May of this year we saw Mr. Goldader for his six-month follow-up appointment. Clinically he is doing very well with no chest pain, shortness of breath or syncopal complaints. He reported that his overall energy level is much improved. An evaluation showed the bioprosthesis is well positioned and functioning normally. He is being followed routinely by his cardiologist.

Aortic Valve Stenosis/TAVR

(continued from previous page)

our TAVR program to encompass more previously untreatable patients."

The TAVR device comprises a balloon-expandable stainless steel frame with bovine pericardial tissue leaflets forming the valve. *(Figure 1)* Rather than opening the chest, the new valve is delivered via a catheter-based approach through a small incision in the femoral artery in the groin. *(Figure 2)* Once in place, the new valve properly controls blood flow. *(Figure 3)* The procedure typically takes two to three hours, and the hospital stay ranges from four to seven days. Postprocedure follow-up appointments are scheduled at one to two weeks, and one, three, six and 12 months, then annually.

In addition to the general AVR evaluation, an echocardiogram and CT scan of the chest, abdomen and pelvis are critical in the final determination that a transcatheter approach using the SAPIEN device is a viable option.

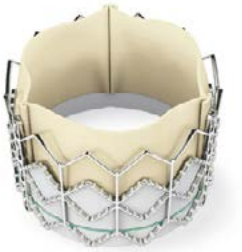

Figure 1

Figure 2

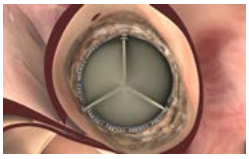

Figure 3

Dedicated and experienced resources

The Swedish TAVR program is an example of how the extensive catheter-based skills of interventional cardiologists and the surgical expertise of cardiothoracic surgeons come together to provide treatment alternatives where none existed previously. The SHVI's dedicated TAVR team includes an echocardiographer, a cardiac anesthesiologist, a radiologist, cardiac nurses, and program and patient care coordinators. The team works seamlessly to initiate testing, evaluate the results and determine the best treatment option.

For more information about surgical or transcatheter aortic valve replacement and for a copy of the SAVR/TAVR Referral Form, go to www.swedish.org/TAVR. Please call **206-320-8100** to consult on a specific patient or to request a second opinion.

When to Refer to Swedish

Structural Heart/TAVR Program
Swedish Heart & Vascular Institute
550 17th Ave., Ste. 680
Seattle, WA 98122
Phone: 206-320-8100
Email: TAVRinformation@swedish.org
Fax: 206-861-8551

The Swedish Heart & Vascular Institute (SHVI) is one of the few medical centers in the United States that offers both conventional and transcatheter aortic valve replacement. Physicians may refer or request a consult anytime they suspect valvular heart disease or have a concern for a heart murmur. Referrals may include patients with:

- Suspected severe aortic stenosis
- Diagnosed aortic stenosis or exam finding of systolic murmur
- Related symptoms, such as the aortic stenosis triad of symptoms: chest pain, syncope or congestive heart failure

SHVI works closely with referring providers to facilitate consultations, and with patients – especially those traveling great distances – to coordinate appointment and evaluation scheduling. More information and a referral form are available online at www.swedish.org/TAVR. Please contact us at 206-320-8100 or TAVRinformation@swedish.org to consult on a patient or to seek a second opinion.

Swedish Health Services Quick Reference

Ballard
5300 Tallman Ave. N.W.
Seattle, WA 98107-3985
206-782-2700

Cherry Hill
500 17th Ave.
Seattle, WA 98122-5711
206-320-2000

Edmonds
21601 76th Ave. W.
Edmonds, WA 98026
425-640-4000

First Hill
747 Broadway
Seattle, WA 98122-4307
206-386-6000

Issaquah
751 N.E. Blakely Dr.
Issaquah, WA 98029
425-313-4000

Mill Creek
13020 Meridian Ave. S.
Everett, WA 98208
425-357-3900

Redmond
18100 N.E. Union Hill Road
Redmond, WA 98052
425-498-2200

Swedish Medical Group
600 University St., Ste. 1200
Seattle, WA 98101-1169
206-320-2700

www.swedish.org/blog
www.facebook.com/swedishmedicalcenter
www.twitter.com/swedish
www.youtube.com/swedishseattle

DocTalk is produced by Swedish Health Services for educational purposes. We invite readers to share their comments and offer suggestions for future topics by contacting us at DocTalk@swedish.org. Archives of articles and case studies previously published in *Physicians Practice* and *DocTalk*, as well as DocTalk videos, are available online at www.swedish.org/DocTalk.

Case studies are provided with the consent of the patient or with personal health information removed or altered in order to protect the patient's privacy.

SWEDISH

SWEDISH HEALTH SERVICES
747 Broadway
Seattle, WA 98122

NON PROFIT
U.S. POSTAGE
PAID
SEATTLE, WA
PERMIT NO. 1564

CME Course Listing – *September – November 2013*

Physicians from across the region and around the world come to Swedish Medical Center's Continuing Medical Education (CME) courses to learn about new research and innovative treatment techniques.

For times and locations, go to www.swedish.org/cme or call 206-386-2755.

Orthopedics Symposium for the Primary-Care Physician
Friday, Sept. 6

Intensive Update in Neurology, 2013
Thursday-Friday, Sept. 12-13

Telehealth: Improving Access to Healthcare
Friday, Sept. 20

17th Annual Pain Management Symposium: Sherlock and the Mystery of Pain
Friday, Sept. 27

Cardiology for the Primary-Care Provider
Friday, Sept. 27

11th Annual West Coast Colorectal Cancer Symposium
Friday, October 25

Transradial Approach: A Case-based and Hands-on Training Course
Friday-Saturday, Nov. 8-9

Diabetes Management Update 2013
Friday, Nov. 15

Controversies in Neurological Restoration: Clinical Strategies and Case Presentations
Friday, Nov. 22

Otolaryngology for the Primary-Care Provider
Friday, Nov. 22

Join our email list at swedish.org/CMEProfile

Like us on Facebook: facebook.com/SwedishCME and follow us on Twitter: twitter.com/SwedishCME

Swedish Medical Center is accredited by the Accreditation Council for Continuing Medical Education to provide continuing medical education for physicians.

The Newest Members of the Swedish Medical Staff

The following individuals joined Swedish during the second quarter of 2013. We invite you to view their online profiles at www.swedish.org/physicians.

Lisa Arnold, CNM *(Midwifery)*
Todd Baumeister, D.O. *(Pain Management)*
Tara Benkers, M.D. *(Neurology)*
Brett Daniel, M.D. *(Family Medicine)*
Aarti Deshpande, M.D. *(Family Medicine)*
Megan Dunn, CNM *(Midwifery)*
Katherine Mayer, M.D. *(Family Medicine w/ Obstetrics)*
Stephen Monteith, M.D. *(Neurosurgery)*
Raanan Odom, M.D. *(Pediatrics)*
Marvin Roman, M.D. *(Family Medicine)*
Kathryn Samaniego, Au.D. *(Podiatry)*
Joseph Simonetti, M.D. *(Internal Medicine/Hospitalist)*
Jo Walker, M.D. *(Family Medicine)*

SWEDISH

© 2013 SWEDISH HEALTH SERVICES. ALL RIGHTS RESERVED.