Lessons Learned From 110 Consecutive VATS Lobectomies For Primary Early-stage NSCLC

SWEDISH CANCER INSTITUTE

Brian E. Louie, Subashini Daniel, Erin Wada, Nancy Tennent, Eric Vallières and Ralph W. Aye

Section of Thoracic and Esophageal Surgery, Swedish Cancer Institute and Medical Center, Seattle, Washington

INTRODUCTION

Approximately 5% of lobectomies for lung cancer are performed using videothoracoscopic (VATS) techniques, but this number is rising. As surgeons begin to integrate VATS techniques into their practices, they will attempt to mimic open surgery via smaller incisions with the goal of performing the same technical operation resulting in similar outcomes. Prior, non-randomized published data suggests similar survival for VATS lobectomy.

The transition from open to VATS techniques may not be identical in patients with presumed early stage lung cancer. Traditional thoracic surgery teaching encourages diagnostic wedge resection or core-needle biopsy for presumed lesions at the time of operation. Pre-operative needle biopsies are irrelevant in this algorithm because a non-diagnostic biopsy would still result in a surgical procedure based on history and radiologic imaging.

We hypothesized that the overall survival and recurrence rates of patients treated by VATS lobectomy is identical to those treated by open lobectomy and that their pre-operative evaluation may require changes to the work up algorithm leading to surgery

METHODS

We performed a retrospective, matched case-control series comparing VATS to open lobectomy to determine our survival and recurrence rates; and, if our pre-operative evaluation of presumed early stage lung cancer required changes.

The entire VATS lobectomy experience performed by a single surgical group from June 1997 to December 2005 for primary, early stage NSCLC was identified and matched for age, gender, tumor type and TNM status with open controls.

Demographic, TNM stage, histopathology, length of stay, local, regional and systemic recurrences and actuarial survival data were analyzed.

Our primary outcomes were:

- 5 - year actuarial survival
- Local recurrence defined as tumor along staple line, adjacent lobe or bronchial stump
- Regional recurrence defined as mediastinal or hilar nodal disease
- Systemic defined as distant lymph node metastases or solid organ involvement

INDICATIONS AND TECHNIQUE

- Clinical stages Ia or b by CT±PET
- Routine mediastinoscopy
- Tumor < 6 cm
- Dissection lobectomy

RESULTS

RESULTS - Overall

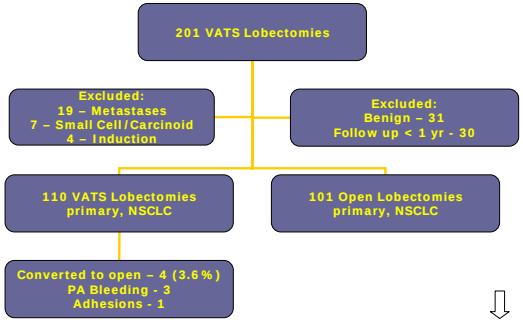

RESULTS -Demographics

	VATS	Open	P-value
Age (yrs)	68.7 ±10.0	68.5 ± 9.0	0.9
Gender (M/F)	54/57	50/45	0.6
Tumor size (cm)	2.7	2.9	0.3
FEV1	81.6 ± 21.8	83.9 ± 20.3	0.6
DLCO	67.1 ± 27.6	64.0 ± 18.4	0.7
LOS	5.3 ± 4.0	7.3 ± 4.6	0.002
Follow up (m)	38 ± 24	36 ± 28	0.60
30 d mortality	2	1	-
RUL	51 (46%)	43 (43%)	
RML	3 (3)	5 (5)	
RLL	20 (18)	14 (14)	-
LUL	24 (22)	13 (13)	
LLL	12 (11)	9 (9)	

RESULTS – Pathology/Histology

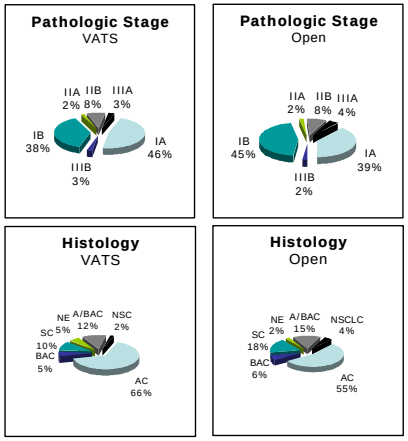

RESULTS – 5-yr Survival

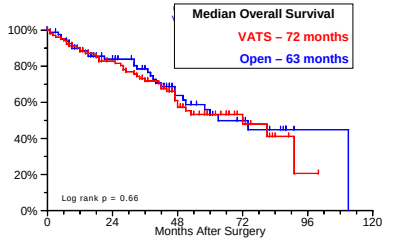

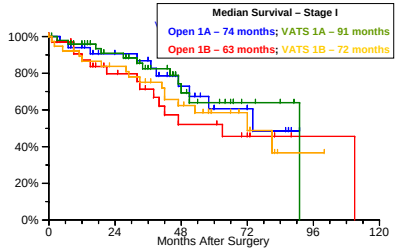

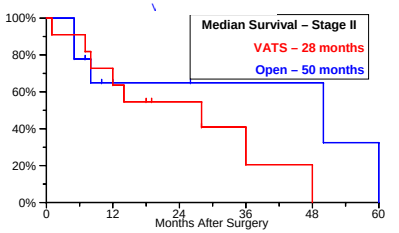

RESULTS - Recurrences

	VATS	OPEN
Local	7	0
Regional	5	3
Systemic	10	22

RESULTS – Local Recurrence Analysis

Case	TNM	Size	Histology	Intervention	Recurrence
187	T1N0	4.5	Adeno/BAC	BAC at fissure	Staple line
190	T1N0	2.0	Adeno/BAC	BAC divided	Pleural
204	T2N0	1.5	Adeno	Divided at wedge	Staple line
154	T4N0	3.5	Adeno (x2)	Unclear	Staple line
183	T1N0	1.1	Adeno	Core biopsy deep	Pleural
167	T2N0	2.0	Adeno	Unclear	Pleural
145	T1N0	1.8	Adeno	PA bleed - conv	Port

PITFALLS AND LESSONS

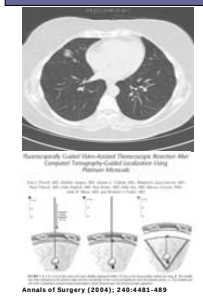
Annals of Surgery (2004); 240:4481-489

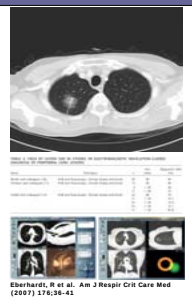
Eberhardt, R et al. Am J Respir Crit Care Med (2007) 176;36-41

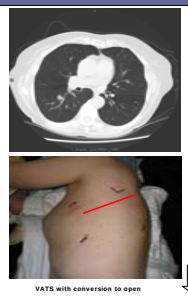
VATS with conversion to open

REVISED TREATMENT ALGORITHM

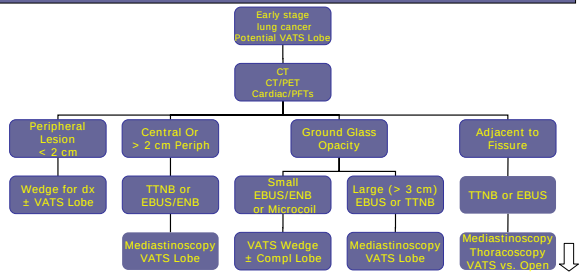

CONCLUSIONS

In our initial experience, we confirmed that VATS lobectomy can be performed safely and that overall survival and survival for pathologic stage Ia and Ib NSCLC are similar when compared to open lobectomy. Local recurrence was higher in the VATS lobectomy group but potentially avoidable by changes in technique. Potential pitfalls for local recurrences include ground glass opacities, large semisolid lesions, deep nodules and nodules adjacent to the fissure.

Changes in preoperative evaluation and surgical decision making were required to adopt and integrate VATS lobectomy into our practice. A higher reliance on obtaining a pre-operative diagnosis in these situations to avoid intra-operative biopsy and adherence to established surgical oncology principles may help reduce local recurrence. We propose a new algorithm to evaluate potential early stage lung cancer patients who may be candidates for VATS lobectomy.